

## Acquired Lymphangioma Circumscriptum Post-neonatal Circumcision

Jad A. Degheili<sup>1\*</sup>, Tag Keun Yoo<sup>2\*</sup>, Sara Trincao-Batra<sup>3</sup>, Jun Ho Lee<sup>2</sup>

<sup>1</sup>Division of Urology, Department of Surgery, Children's Hospital of Eastern Ontario, Ottawa, Ontario, Canada

<sup>2</sup>Department of Urology, Nowon Eulji Medical Center, Eulji University School of Medicine, Seoul, Republic of Korea

<sup>3</sup>Faculty of Medicine, University of Ottawa, Ontario, Canada

\*These authors have contributed equally to this work.

A 9-year-old boy presented from the rural countryside to the urology outpatient department with a chief complaint of genital edema and multiple painless blisters, occasionally rupturing and draining clear fluid (Figure 1). At 20 days of age, he underwent an uncomplicated circumcision. Two weeks later, the parents noticed penile and scrotal edema, with protruding vesicles from the perineal and scrotal skin. Seen by several local dermatologists during all this period, he was treated on several occasions, with liquid nitrogen for the vesicles and Molutrex solution, supposedly treating molluscum contagiosum. Minimal improvement was noted.

Upon presentation, a testicular ultrasound showed normal-sized testicles, the right side measuring 20 × 13 mm, and the left-sided testicle measuring 19 × 14 mm. No inter-parenchymal masses or nodes were visible. Bilateral moderate-sized hydroceles were noted. An ultrasound of the abdomen showed normal-sized kidneys, with no ascites or any other intra-abdominal lesions.

To better characterize the extent of the external genitalia's edema and to identify any soft tissue abnormalities, an unenhanced magnetic resonance imaging of the pelvis was performed. Soft tissue edema was noted within the scrotum, penile shaft, and perineal area, along with noted vesicles (Figure 2). Bilateral moderate hydroceles were also noted. Based on the clinical picture and radiological images, a preliminary diagnosis of lymphangioma circumscriptum (LC) was made. A reconstructive surgery was offered as an option with the possibility of recurrence, but the family declined at this point.

LC is a rare superficial cutaneous lymphatic malformation, presenting at birth or acquired later in life, secondary to infection, surgery, or radiation.<sup>1</sup>

The fact that our patient underwent a circumcision, despite no records for how extensive the procedure was or any possible complications, could have impacted the normal lymphatic drainage of the tissues, within the groin area, leading to an acquired form of LC, despite patient's young age.

Initially, Fox and Fox<sup>2</sup> in 1878 highlighted the cause of LC as deep subcutaneous lymphatic cisterns that are not connected to the lymphatic system. Upon contraction, a back pressure occurs; thus transmitted to the epidermis, resulting in translucent vesicles resembling a frog spawn.<sup>3</sup> LC involves the thighs, buttocks, groin, and axilla; rarely involving the genitalia such as the scrotum.<sup>4,5</sup> Infectious etiologies such as molluscum contagiosum, filariasis, and condylomata accuminata must be ruled out.<sup>1</sup> LC is generally a benign disease, but reports of lymphangiosarcoma and malignant transformation to squamous cell carcinoma have been reported in a long-standing history of LC.<sup>3</sup> The differential diagnosis for LC is wide, and each must be ruled out clinically and sometimes with the utility of histopathological biopsies. These include dermatitis herpetiformis, herpes zoster, lymphangiectasia, and various dermatological manifestations of herpes simplex, metastatic malignancies, such as melanoma, and neurofibromatosis type I, among few others.<sup>6</sup>

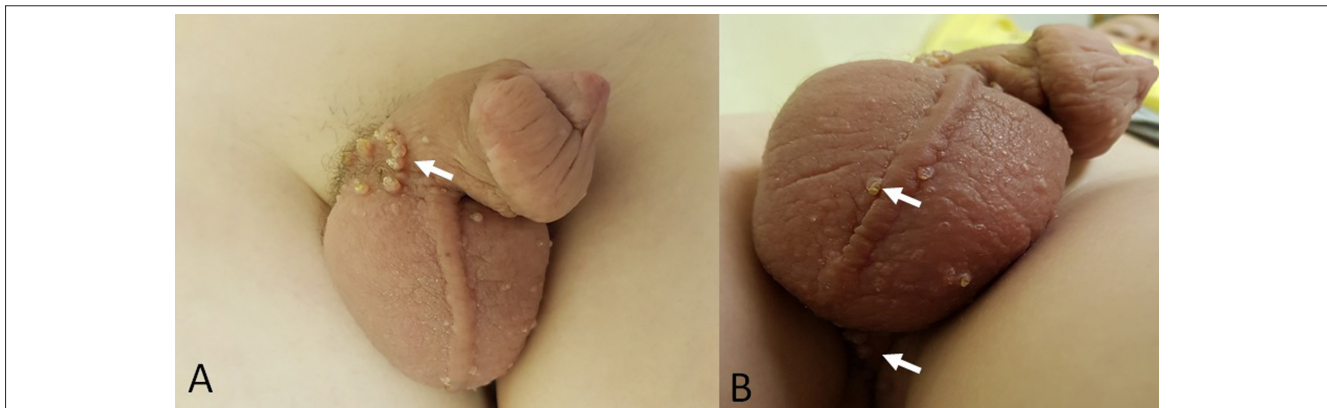
### Corresponding author:

Jad A. Degheili  
✉jdegheili@cheo.on.ca;  
jdegheili@gmail.com  
Received: February 24, 2021  
Accepted: April 1, 2020

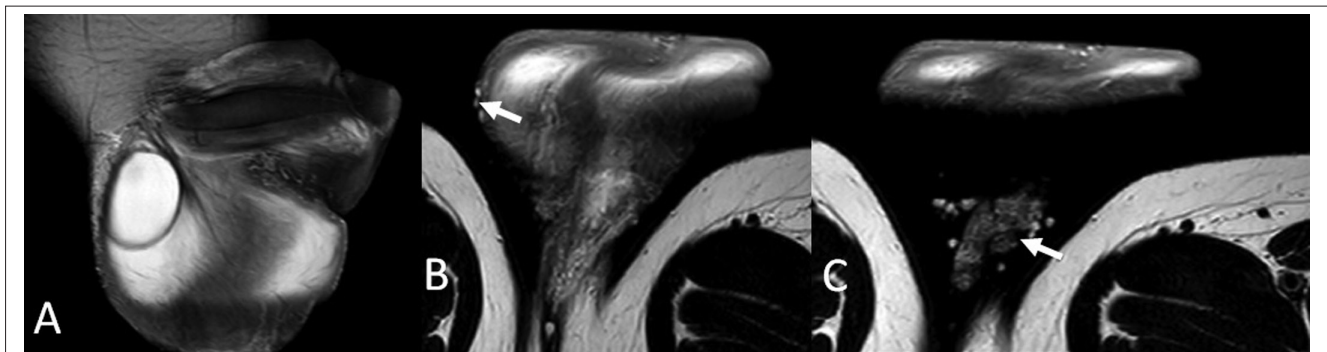
Content of this journal is licensed  
under a Creative Commons  
Attribution-NonCommercial 4.0  
International License.



**Cite this article as:** A. Degheili J, Keun Yoo T, Trincao-Batra S, Ho Lee J. Acquired lymphangioma circumscriptum post-neonatal circumcision. *Turk Arch Pediatr.* 2021; 56(5): 539-540.



**Figure 1. a, b.** Gross image of the patient's genitalia. (a) Presence of translucent vesicles at the penoscrotal junction and significant edema of the penile shaft and scrotum. (b) Few more of those vesicles seen at the scrotum and the perineal area (arrows), resembling a frog spawn.



**Figure 2. a-c.** Magnetic resonance imaging (MRI) of the pelvis. (A) Pelvic MRI shows significant edema of the penis and the scrotum, along with bilateral hydroceles. (B&C) Evident fluid-filled vesicles on the scrotal skin and the perineal area (arrows).

Although less invasive treatment modalities such as cryotherapy, sclerotherapy, and radiofrequency ablation are utilized, surgical resection of the deep lymphatic cysts represents the only definitive cure.<sup>7</sup> Kumar et al.<sup>5</sup> presented the first case of penoscrotal LC, acquired four months following circumcision. This was treated with excessive surgical resection, followed by raising flaps and a split-thickness skin graft. A potential cause for acquired LC, postcircumcision, could be secondary to manhandling of tissues; yet the exact pathophysiology remains indeterminate.<sup>5</sup> Failure of adequate excision leads to recurrence in 25-50% of cases, within 3 months.<sup>4</sup>

**Informed Consent:** Written informed consent was obtained from all participants who participated in this study.

**Peer Review:** Externally peer-reviewed.

**Author Contributions:** Concept - J.A.D., T.K.Y.; Design - J.A.D., T.K.Y., J.H.L.; Supervision - J.A.D., T.K.Y., J.H.L.; Resource - J.A.D., S.T.B.; Materials - J.A.D., T.K.Y., S.T.B., J.H.L.; Data Collection and/or Processing - J.A.D., T.K.Y., J.H.L.; Analysis and/or Interpretation - J.A.D., T.K.Y., S.T.B., J.H.L.; Literature Search - J.A.D., S.T.B.; Writing - J.A.D., T.K.Y., J.H.L.; Critical Reviews - J.H.L., S.T.B.

**Conflict of Interest:** The authors have no conflicts of interest to declare.

**Financial Disclosure:** The authors declared that this study has received no financial support.

## REFERENCES

1. Haroon S, Hasan SH. Lymphangioma circumscriptum in the scrotum: a case report. *J Med Case Rep.* 2012;6:233. [CrossRef]
2. Mordehai J, Kurzbar E, Shinhar D, et al. Lymphangioma circumscriptum. *Pediatr Surg Int.* 1998;13:208-210. [CrossRef]
3. Savas JA, Graham GF. Lymphangioma circumscriptum. In: Abramovits W, Graham G, Har-Shai Y, Strumia R, eds. *Dermatological Cryosurgery and Cryotherapy.* Springer, London; 2016.
4. Avhad G, Jerajani H. Lymphangioma circumscriptum of the male genitalia. *Indian Dermatol Online J.* 2016;7:68-69. [CrossRef]
5. Kumar S, Mittal A, Chandna A. Penoscrotal lymphangioma circumscriptum following circumcision. *Turk J Urol.* 2018;44:437-440. [CrossRef]
6. Miceli A, Stewart KM. Lymphangioma. In: *Stat Pearls* [Internet]. Treasure Island: StatPearls Publishing. 2021. <https://www.ncbi.nlm.nih.gov/books/NBK470333/>.
7. Puri N. Treatment options of lymphangioma circumscriptum. *Indian Dermatol Online J.* 2015;6(4):293-294.